

## Laryngeal papillomatosis with human papillomavirus DNA contracted by a laser surgeon

P. Hallmo<sup>1</sup> and O. Naess<sup>2</sup>

Departments of <sup>1</sup>Otorhinolaryngology and <sup>2</sup>Pathology, Ullevaal Hospital, Oslo, Norway

Received December 10, 1990 / Accepted March 7, 1991

**Summary.** A 44-year-old laser surgeon presented with laryngeal papillomatosis. In situ DNA hybridization of tissue from these tumors revealed human papillomavirus DNA types 6 and 11. Past history revealed that the surgeon had given laser therapy to patients with anogenital condylomas, which are known to harbor the same viral types. These findings suggest that the papillomas in our patient may have been caused by inhaled virus particles present in the laser plume.

**Key words:** Laser vapor – Human papillovirus DNA contamination – Laser surgeon

### Introduction

The possibility that laser surgeons might inhale virus particles from laser vapor during the removal of certain lesions has been pointed out by several authors [3, 9, 18]. The risk, however, is regarded as being low, provided adequate precautions are taken. Safety procedures related to eye protection, smoke evacuator systems, etc. have been established [12, 19, 20].

Human papillomavirus (HPV) is considered to be the most important potential agent for transmission from patient to surgeon through smoke plume from lasers. To our knowledge though, no case has been reported describing contamination of members of laser teams. Here we present a case of laryngeal papillomatosis where this mode of infection seems likely.

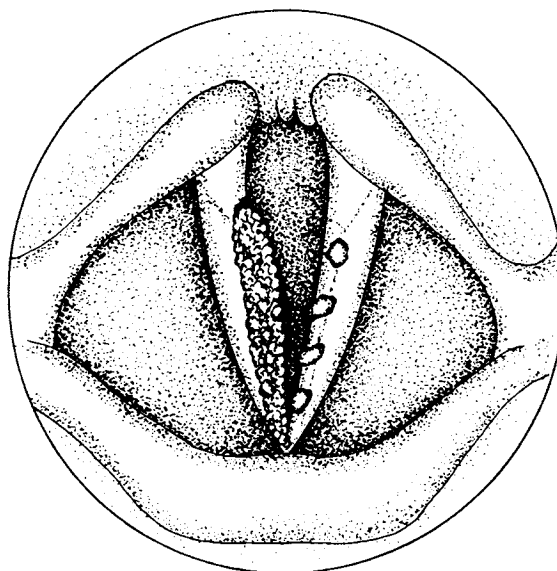
### Case report

In May 1990 a 44-year-old male laser surgeon consulted the Department of Otorhinolaryngology because of hoarseness of 6 months' duration. He had no respiratory

distress and was otherwise healthy. He did not smoke and used no medicine. His wife had no history of anogenital condylomas.

From November 1987 until the present date, he had performed several therapeutic procedures with the Nd:YAG laser, the lesions primarily involving 55 cancers in the distal colon and rectum, but also 5 patients with anogenital condyloma acuminata. The hospital possessed no laser smoke evacuator system except for the built-in suction in the endoscope used for treatment of intraluminal cancers. During treatment of the condylomas, an ordinary smoke evacuator was used, in addition to conventional masks, gloves and eye protection. The Nd:YAG laser had a maximum power of 100 W.

Laryngoscopy of the patient revealed large, confluent papillomatous masses in the anterior laryngeal commis-



**Fig. 1.** Schematic figure of the larynx showing the localization of the papillomas



**Fig. 2.** In situ hybridization with biotinylated DNA probe against human papillomavirus (HPV) type 6. HPV type 6 viral particles are present within several nuclei of the tumor. HPV type 11 revealed similar results (not shown)

sure and along most of the right vocal cord (Fig. 1). Four smaller, discrete, smooth papillomas were situated along the cranial and medial surfaces of the left cord. Flexible bronchoscopy revealed no further papillomas in the respiratory tract. Additional clinical examination as well as routine blood tests were normal.

Biopsies of the laryngeal lesions showed squamous papillomas with moderate focal dysplasia. In situ DNA hybridization with DNA probes of HPV types 6, 11, 16, 18, 31, 33, and 35 was carried out [22] using "Vira Type" (Life Technologies, Gaithersburg, Md., USA) and "Pathogene" (Enzo Diagnostics, New York, N.Y., USA). DNA from HPV types 6 and 11 was identified in groups of the tumor cells (Fig. 2), while the other probes were negative.

Management of the laryngeal papillomas required one removal from each vocal cord with a CO<sub>2</sub> laser. Postoperatively no papillomas have been seen, and his previous voice quality has been restored.

## Discussion

Respiratory papillomas are usually divided into juvenile-onset and adult-onset forms. In children the multiple type is by far the most frequent, whereas in adults the majority of papillomata are solitary [2, 11, 14]. However, differentiation by type can seldom be made on histological grounds alone [13, 21]. In general, lesions are most often seen on the vocal folds, although the rest of the respiratory tract as well as the pharynx and oral cavity may be affected. In children growth of papillomas is often extensive, with multiple recurrences following repeated removals, while in adults the disease is usually less aggressive [11, 25]. Adults also often lack respiratory distress in their presenting symptomatology [2].

The cause of respiratory papillomatosis remains unknown, although strong evidence supports a viral theory. HPV DNA types 6 and 11 have been demonstrated both in laryngeal papillomas [7, 24, 26] and in anogenital con-

dylomas [8, 10, 26]. Retrospective studies have supported a possible causal relationship between maternal genital condylomas and juvenile papillomatosis [6, 16]. Pathogenesis is more uncertain for the adult-onset form of papillomatosis, although some adult cases may have been infected through oral-genital contact by sexual partners with genital warts [5, 21, 23].

In our present case there was no known source of infection other than the surgeon's own patients. This occurred most likely from his exposure to the anogenital condylomas known to harbor HPV types 6 and 11. Although it has been shown that HPV infections may play a role in the development of anal squamous carcinomas [26], the suspected viruses in these cases have been of the HPV 16 and 18 types. The usual incubation time for developing condylomas is from 1 month to several months [15].

Thus, any of the patients with anogenital warts could have been the source contaminating our patient during laser surgery.

There is little evidence in the literature contradicting our view concerning contamination of our patient. Intact HPV has been demonstrated in the CO<sub>2</sub>-laser plume from plantar or mosaic warts [9, 17] and anogenital condylomas [3, 8]. Additionally, Sawchuk et al. [18] observed infectious bovine papilloma virus in vapor from bovine warts. Furthermore, they found the amount of HPV DNA to be proportional to the amount of viruses present in the treated warts. Sawchuk and Felten [17] have indicated that smoke from genital warts will generate only a small amount of infectious material. Additionally, several authors have concluded that the danger of viral transmission to surgical personnel during surgery is quite small [8, 17, 18]. This is probably correct, though the amounts of viral particles stated in different reports have been relatively small [3, 8, 9, 17, 18]. The reason for this is the different levels of detection used and the fact that the number of HPV-contaminating cells may be small and not equally distributed in tumor tissue. However, in agreement with the reports cited, an important point to realize is that there *does* exist a risk for laser teams.

Like other authors, we believe that a well-functioning laser smoke evacuator device adjacent to the operating field is of greatest importance to the laser team. This probably also holds true for the use of special surgical masks with pore sizes designed to protect clinicians from inhaling small-diameter particles [17]. In contrast to the findings of Sawchuk et al. [18], our present case seems to indicate that ordinary masks may provide an ineffective barrier to HPV DNA. Another possible explanation might be that our patient's face mask had a less than perfect fit. It seems unlikely that our patient could have been infected by directly or indirectly touching the surgical area, which is the most common mode of contamination [1].

Although the exact mechanism of contamination in our patient cannot be proven, the risk for the laser team during the removal of any virally induced neoplasm should be regarded as more than a theoretical possibility. This is supported by the fact that there has been a

noticeable increase in medical consultations due to anogenital lesions caused by HPV in recent years [4]. Equipment which provides optimal protection against inadvertent contamination should therefore be obligatory for every laser team.

## References

- Abramson AL, DiLorenzo TP, Steinberg BM (1990) Is papillomavirus detectable in the plume of laser-treated laryngeal papilloma? *Arch Otolaryngol Head Neck Surg* 116: 604–607
- Alberti PW, Dykun R (1981) Adult laryngeal papillomata. *J Otolaryngol* 10: 463–470
- Andre P, Orth G, Evenou P, Guillaume JC, Avril MF (1990) Risk of papillomavirus infection in carbon dioxide laser treatment of genital lesions. *J Am Acad Dermatol* 22: 131–132
- Becker TM, Stone KM, Alexander ER (1987) Dramatic increase in consultation for genital warts in recent years. *Obstet Gynecol Clin North Am* 14: 389–396
- Bender ME (1986) New concepts of condylomata acuminata in children. *Arch Dermatol* 122: 1121–1123
- Cook TA, Brunschwig JP, Butel JS, Cohn AM, Goepfert H, Rawls WE (1973) Laryngeal papilloma: etiologic and therapeutic considerations. *Ann Otol Rhinol Laryngol* 82: 649–655
- Duggan MA, Lim M, Gill MJ, Inoue M (1990) HPV DNA typing of adult-onset respiratory papillomatosis. *Laryngoscope* 100: 639–642
- Ferenczy A, Bergeron C, Richart RM (1990) Human papillomavirus DNA in CO<sub>2</sub> laser-generated plume of smoke and its consequences to the surgeon. *Obstet Gynecol* 75: 114–118
- Garden JM, O'Banion MK, Shelnitz LS, Pinski KS, Bakus AD, Reichmann ME, Sundberg JP (1988) Papillomavirus in the vapor of carbon dioxide laser-treated verrucae. *JAMA* 259: 1199–1202
- Gissmann L, Wolnik L, Ikenberg H, Koldovsky U, Schnürch HG, zur Hausen H (1983) Human papillomavirus types 6 and 11 DNA sequences in genital and laryngeal papillomas and in some cervical cancers. *Proc Natl Acad Sci USA* 80: 560–563
- Holinger PH, Johnston KC, Anison GC (1950) Papilloma of the larynx: a review of 109 cases with a preliminary report of aureomycin therapy. *Ann Otol* 59: 547–564
- IEC standard 825 (1984) Radiation safety of laser products, equipment classification, requirements and user's guide. IEC, Geneva
- Kleinsasser O, Oliviera E, Cruz G (1973) Übersichten: "Juvenile" and "adulte" Kehlkopfapillome. *HNO* 21: 97–103
- Lindeberg H, Øster S, Oxlund I, Elbrønd O (1986) Laryngeal papillomas: classification and course. *Clin Otolaryngol* 11: 423–429
- Noble RC (1982) Sexually transmitted diseases. Guide to diagnosis and therapy. Medical Examination Publishing Co., Garden City, NY, pp 80–87
- Quick CA, Krzyzek RA, Watts SL, Faras AJ (1980) Relationship between condylomata and laryngeal papillomata. Clinical and molecular virological evidence. *Ann Otol Rhinol Laryngol* 89: 467–471
- Sawchuk WS, Felten RP (1989) Infectious potential of aerosolized particles (editorial). *Arch Dermatol* 125: 1689–1692
- Sawchuk WS, Weber PJ, Lowy DR, Dzubow LM (1989) Infectious papillomavirus in the vapor of warts treated with carbon dioxide laser or electrocoagulation: detection and protection. *J Am Acad Dermatol* 21: 41–49
- Schröder E (1989) Safety aspects. In: Riemann JF, Ell C (eds) *Lasers in gastroenterology*. Thieme, Stuttgart, pp 156–160
- Sliney DH (1989) Laser safety in general surgery. In: Joffe SN (ed) *Lasers in general surgery*. Williams and Wilkins, Baltimore, pp 16–24
- Strong MS, Vaughan CW, Cooperband SR, Healy GB, Clemente MAC (1976) Recurrent respiratory papillomatosis. Management with the CO<sub>2</sub> laser. *Ann Otol Rhinol Laryngol* 85: 508–516
- Syrjänen S, Partanen P, Mäntyjärvi R, Syrjänen K (1988) Sensitivity of in situ hybridization techniques using biotin- and 35S-labeled human papillomavirus (HPV) DNA probes. *J Virol Methods* 19: 225–238
- Teokharov BA (1969) Non-gonococcal infections of the female genitalia. *Br J Vener Dis* 45: 334–340
- Terry RM, Lewis FA, Griffiths S, Wells M, Bird CC (1987) Demonstration of human papillomavirus types 6 and 11 in juvenile laryngeal papillomatosis by in-situ DNA hybridization. *J Pathol* 153: 245–248
- Weiss MD, Kashima HK (1983) Tracheal involvement in laryngeal papillomatosis. *Laryngoscope* 93: 45–48
- Wells M, Griffiths S, Lewis F, Bird CC (1987) Demonstration of human papillomavirus types in paraffin processed tissue from human anogenital lesions by in-situ DNA hybridisation. *J Pathol* 152: 77–82